Pediatric Obstructive Sleep Apnea: Consensus, Controversy, and Craniofacial Considerations

Ravi K. Garg, M.D.
Ahmed M. Afifi, M.D.
Catharine B. Garland, M.D.
Ruston Sanchez, M.D.
Delora L. Mount, M.D.

Madison, Wis.; and Cairo, Egypt

Summary: Pediatric obstructive sleep apnea, characterized by partial or complete obstruction of the upper airway during sleep, is associated with multiple adverse neurodevelopmental and cardiometabolic consequences. It is common in healthy children and occurs with a higher incidence among infants and children with craniofacial anomalies. Although soft-tissue hypertrophy is the most common cause, interplay between soft tissue and bone structure in children with craniofacial differences may also contribute to upper airway obstruction. Snoring and work of breathing are poor predictors of obstructive sleep apnea, and the gold standard for diagnosis is overnight polysomnography. Most healthy children respond favorably to adenotonsillectomy as first-line treatment, but 20 percent of children have obstructive sleep apnea refractory to adenotonsillectomy and may benefit from positive airway pressure, medical therapy, orthodontics, craniofacial surgery, or combined interventions. For children with impairment of facial skeletal growth or craniofacial anomalies, rapid maxillary expansion, midface distraction, and mandibular distraction have all been demonstrated to have therapeutic value and may significantly improve a child's respiratory status. This Special Topic article reviews current theories regarding the underlying pathophysiology of pediatric sleep apnea, summarizes standards for diagnosis and management, and discusses treatments in need of further investigation, including orthodontic and craniofacial interventions. To provide an overview of the spectrum of disease and treatment options available, a deliberately broad approach is taken that incorporates data for both healthy children and children with craniofacial anomalies. (*Plast. Reconstr. Surg.* 140: 987, 2017.)

Obstructive sleep apnea is estimated to occur in 1 to 3 percent of the general pediatric population[1]; 22 to 65 percent of children with cleft lip and/or palate[2]; 40 to 68 percent of children with Apert, Crouzon, and Pfeiffer craniosynostosis syndromes[3,4]; and 85 percent of infants with Pierre Robin sequence who undergo polysomnography.[5] Given the prevalence of obstructive sleep apnea in the general pediatric population, the particularly high incidence of obstructive sleep apnea among infants and children seen in craniofacial centers, and our increasing understanding of how craniofacial skeletal morphology impacts upper airway patency, it is critical that plastic surgeons have a thorough understanding of current diagnostic and treatment approaches to obstructive sleep apnea and controversies in the management of pediatric obstructive sleep apnea.

Undiagnosed or untreated pediatric obstructive sleep apnea has been associated with learning impairment and behavioral problems such as hyperactivity and aggression.[6] More serious sequelae include developmental and neurological delay, failure to thrive, and cardiovascular disease, including pulmonary hypertension and right ventricular hypertrophy.[7,8] Treatment of children with adenotonsillectomy, the first-line treatment recommended for most children by the American Academy of Pediatrics,[9] has been associated with improvements in behavior,[10] school performance,[11] and right ventricular hypertrophy.[12]

From the Division of Plastic and Reconstructive Surgery, Department of Surgery, University of Wisconsin; and the Division of Plastic Surgery, Cairo University.
Received for publication January 24, 2017; accepted March 31, 2017.
Copyright © 2017 by the American Society of Plastic Surgeons
DOI: 10.1097/PRS.0000000000003752

Disclosure: *The authors have no financial interest to declare in relation to the content of this article.*

Copyright © 2017 American Society of Plastic Surgeons. Unauthorized reproduction of this article is prohibited.

Despite the success of adenotonsillectomy, approximately 20 percent of children in the general population have residual obstructive sleep apnea after this procedure.[8,13] Alternatively, patients cured in childhood may have recurrence of obstructive sleep apnea in adolescence, characterized by nighttime snoring and pauses in breathing.[14,15] For these patients with recurrent or residual obstructive sleep apnea following adenotonsillectomy, there is a lack of evidence to guide management. An institutional analysis of decision-making for children with obstructive sleep apnea and no tonsillar hypertrophy revealed that only 34 percent of decisions were evidence-based.[16] Often, the treatment a child receives is the consequence of which subspecialist they visit rather than evidence-based guidelines,[17] and many procedures including craniofacial distraction lack high-quality outcomes data.[13,18]

Because of the paucity of quantitative data surrounding treatments for pediatric obstructive sleep apnea, the field is wide open for plastic surgeons and colleagues in associated disciplines to develop more rigorous diagnostic and treatment protocols. The goal of this review is to synthesize current knowledge of pediatric obstructive sleep apnea to inform evolving management strategies for this problem.

PATHOPHYSIOLOGY

Pediatric obstructive sleep apnea is a form of sleep-disordered breathing distinct from other hypoventilation disorders including apnea of prematurity and central sleep apnea. It has been characterized by the American Thoracic Society as a disorder involving prolonged partial upper airway obstruction and/or intermittent complete obstruction that disrupts sleep patterns and ventilation during sleep.[19] Unlike in adults, partial upper airway obstruction is common in children and sufficient to cause harmful sequelae because of decreased pulmonary reserve.[20] Upper airway obstruction may occur at multiple levels, including the nasal vault, oral cavity, pharynx, larynx, and trachea. We first briefly discuss obstruction occurring in the context of (1) immaturity or dysregulation of the upper airway neuromotor system, and (2) soft-tissue enlargement caused by lymphoid tissue hypertrophy or obesity. The next section then focuses on morphologic constraints imposed by the craniofacial skeleton.

Neuromotor dysregulation may occur as part of a genetic syndrome or during normal development, particularly among infants whose respiratory systems are still maturing. Healthy infants may experience central apneic events, periodic breathing, and mixed apneic events characterized by periods of absent and active inspiratory effort.[21–23] Furthermore, infants have a predominance of rapid eye movement sleep early in life during which there is a decrease in motor tone throughout the upper airway.[22,23] As sleep patterns mature, apneic events become less frequent in healthy children. However, children with obstructive sleep apnea have upper airways more prone to collapse and a blunted arousal response to hypercapnia.[24,25] Ongoing apneic events in these children usually occur during rapid eye movement sleep.[26]

Soft-tissue hypertrophy is a common cause for upper airway narrowing in children with obstructive sleep apnea. In fact, adenotonsillar hypertrophy peaks at 3 to 7 years of age and coincides with the peak incidence of childhood obstructive sleep apnea.[27,28] Enlarged tonsils and adenoids are a well-accepted target for intervention among healthy children. In children with craniosynostosis syndromes, efficacy data for adenotonsillectomy are mixed because these children are more likely to have multilevel airway obstruction.[29–31] Although less common in children than adults, obesity also places children at risk of upper airway obstruction, as fat deposition around the pharynx impinges on the upper airway.[32,33]

CRANIOFACIAL CONTRIBUTIONS

Craniofacial skeletal morphology plays an important role in the patency of the upper airway in both healthy children and children with craniofacial anomalies. Here we review what is known about the contribution of the craniofacial skeleton to pediatric obstructive sleep apnea in children who are healthy, have cleft lip and/or palate, or have a craniofacial anomaly. Other important upper airway anomalies such as choanal atresia, piriform aperture stenosis, laryngomalacia, and subglottic stenosis are beyond the scope of this review.[23]

Healthy Children

Cephalometric studies have shown that children with adenotonsillar hypertrophy and obstructive sleep apnea have craniofacial features associated with multilevel upper airway narrowing. Compared to children without obstructive sleep apnea, the posterior airway space is smaller, the mandible is retruded, the occlusal and mandibular planes are more vertically oriented, and the lower face is longer.[34,35] The hyoid bone may also be positioned lower,[36] although some data suggest that its position may be unchanged or superiorly

Copyright © 2017 American Society of Plastic Surgeons. Unauthorized reproduction of this article is prohibited.

oriented in relation to the mandibular plane.[37,38] Many of these relationships are also observed among adults with obstructive sleep apnea.[37]

The long, retrusive facial characteristics observed among healthy children with obstructive sleep apnea are hypothesized to occur because of muscular forces on the developing craniofacial skeleton (Fig. 1). As adenoid tissue hypertrophies and obstructs nasal airflow, children assume an extended head posture to increase the volume of the retroglossal and hypopharyngeal airway.[39] Head extension causes the investing fascia of the neck to exert a caudal pull on the mandible, which may lead to a more vertical growth pattern.[40,41] These children also resort to mouth breathing, resulting in caudal tongue movement and medialization of the buccal musculature against the maxilla, which may contribute to transverse maxillary constriction.[42]

It remains unknown whether the craniofacial morphology of children with obstructive sleep apnea results strictly from adaptive musculoskeletal imbalances in the setting of adenotonsillar hypertrophy, or whether there are other important developmental or genetic determinants. Some authors suggest a predominant role for adenotonsillar hypertrophy, as adenoidectomy has been associated with acceleration of mandibular growth and correction of dentofacial relationships such as the mandibular plane angle.[43] However, there is also evidence that children who have undergone adenotonsillectomy maintain dental and craniofacial differences from healthy children, indicating persistence of craniofacial morphologic changes.[42,44]

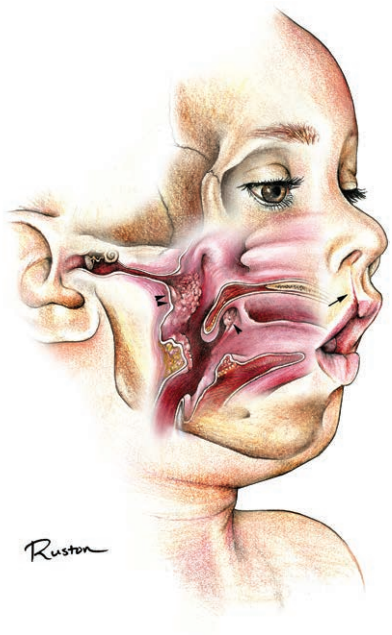

Fig. 1. This child has "adenoid facies," a term commonly used to describe facial characteristics of a mouth-breathing child with a long anterior face and retrusive mandible. It is theorized that nasal obstruction occurring as a result of multiple causes, ranging from adenoid (double arrowhead) and tonsillar (single arrowhead) hypertrophy to nasal vestibular stenosis following cleft lip and palate repair (arrow), may predispose children to mouth breath. Habitual mouth breathing alters the fascial and muscular force vectors on the developing craniofacial skeleton, potentially leading to long-term changes in craniofacial morphology. As a consequence, children may develop a long anterior face with retrognathia and compromised horizontal growth.

Cleft Lip and/or Palate

Children with a history of cleft palate with or without cleft lip have been demonstrated to be at significantly increased risk of obstructive sleep apnea. A retrospective review of children with cleft palate with or without cleft lip revealed symptoms of sleep-disordered breathing to be present among 34 percent of patients with a syndromic diagnosis and 17 percent of nonsyndromic children.[45] Adenotonsillectomy and continuous positive airway pressure were common treatments that improved patients' obstructive sleep apnea, although most still had residual disease. Perhaps the most important finding from this study was that 98 percent of sleep studies ordered were abnormal and that sleep-disordered breathing is likely to be underreported and undertreated among children with a history of cleft palate.

Craniofacial morphologic findings of children with cleft palate with or without cleft lip are similar to those described for healthy children with adenotonsillar hypertrophy and may relate to compensatory head positioning in the setting of nasal obstruction from septal deviation, palatal scarring, or growth impairment.[2,36] Cephalometric studies of children with cleft palate with or without cleft lip before repair of the palate have demonstrated features of a short anterior skull base, maxillomandibular retrusion, and vertically oriented occlusal and mandibular planes.[46,47] Following palate repair, children continue to demonstrate these morphologic findings.[48,49] As with healthy children, it has been theorized that, over time, craniofacial morphologic changes that were initially compensatory may actually direct facial growth more caudally, compromising the airway.[36]

Children with histories of cleft repair are also at risk of upper airway obstruction from the palate repair itself, particularly in scenarios where additional surgery was performed to correct velopharyngeal dysfunction. Posterior pharyngeal

Copyright © 2017 American Society of Plastic Surgeons. Unauthorized reproduction of this article is prohibited.

wall augmentation, sphincter pharyngoplasty, and pharyngeal flap surgery have been associated with obstructive sleep apnea.[50–52] Pharyngeal flap surgery has the strongest association with obstructive sleep apnea, with reported rates as high as 38 to 93 percent.[53,54] Flap takedown in these instances is usually necessary and sufficient to resolve the obstructive sleep apnea. Interestingly, improvements in speech from the initial pharyngeal flap surgery can be maintained after flap takedown.[54]

Craniofacial Anomalies

Children with craniofacial anomalies relating to craniosynostosis syndromes, Treacher Collins syndrome, hemifacial microsomia, Down syndrome, and Pierre Robin sequence have been reported to have a high incidence of obstructive sleep apnea.[55,56] A prospective study of children with syndromic craniosynostoses identified a 68 percent prevalence of obstructive sleep apnea,[4] and a study of children with craniofacial malformations and symptoms concerning for sleep-disordered breathing identified an 87 percent prevalence of obstructive sleep apnea.[57]

Obstruction may occur anywhere along the upper airway,[58] although strong correlations have been made between obstructive sleep apnea and the presence of facial skeletal dysmorphology in children with craniofacial anomalies. One study reported a need for airway intervention in 42 percent of children with midface hypoplasia, 71 percent of children with midface and mandibular hypoplasia, and 72 percent of children with mandibular hypoplasia.[59] Among patients with craniosynostosis, a prospective study identified a greater severity of obstructive sleep apnea among children with associated midface hypoplasia.[4] Although children with craniosynostosis and no midface hypoplasia experienced improvement in the severity of their obstructive sleep apnea over time, children with combined craniosynostosis and midface hypoplasia did not experience this improvement.[4]

The spectrum of skeletal and soft-tissue differences that distinguish each craniofacial syndrome is extensive. Basic skeletal distinctions include the presence of a concave facial profile among children with Crouzon and Apert syndrome. Children with Apert syndrome also have midfacial concavity on worm's-eye view because of the central midface being more posteriorly positioned than the zygomas.[60] Children with Pierre Robin sequence and Treacher Collins syndrome, in contrast, tend to have convex facial profiles, with smaller mandibles. Furthermore, children with Treacher Collins syndrome are characterized by orbitozygomatic deficiency.[61,62]

Despite differences in these syndromes and their facial appearances, some craniofacial skeletal similarities may be associated with obstructive sleep apnea. Children with Apert and Crouzon syndromes, Pierre Robin sequence, and Treacher Collins syndrome have all been demonstrated to have short anterior skull base measurements relative to the norm, and these abnormalities in skull base growth may contribute to midface hypoplasia.[61,63–66] The anterior skull base forms the roof of the orbit and midface and therefore determines the depth and projection of the midface. The angulation of the posterior skull base relative to the anterior skull base may impact the anteroposterior and vertical position of the mandible and the volume of the pharyngeal airway.[66,67] Interestingly, children with Apert syndrome, Treacher Collins syndrome, and Pierre Robin sequence have been observed to have a more steeply inclined mandibular plane and retrognathia,[61–63] anatomical findings likely associated with a small posterior airspace.

EVALUATION AND DIAGNOSIS

The American Academy of Pediatrics has issued obstructive sleep apnea screening guidelines for healthy children, recommending routine questioning about snoring during clinic visits.[68] A polysomnogram, however, is necessary to make an official diagnosis, as history and physical examination have low sensitivity and specificity in screening for obstructive sleep apnea.[69,70] A polysomnogram is an overnight study that monitors electroencephalography, pulse oximetry, oronasal airflow, abdominal and chest wall movements, and carbon dioxide partial pressure.[68] Scoring of pauses in breathing and decreases in airflow leads to numeric metrics such as the apnea-hypopnea index that are used to grade obstructive sleep apnea severity (Table 1).

Scoring of sleep apnea severity for infants and children is different from scoring for adults because of differences in sleep patterns and pulmonary reserve.[71] There is also a lack of consensus regarding how polysomnographic data correlate with true sleep abnormality, particularly in infants, who experience central apneic events early in life as part of normal development and fewer central events as they mature.[72] The numeric cutoff for what is normal remains a subjective decision. In addition, controversy exists regarding scoring of obstructive sleep apnea in adolescents, and

Copyright © 2017 American Society of Plastic Surgeons. Unauthorized reproduction of this article is prohibited.

Table 1. Sleep Apnea Characteristics and Definitions for Infants and Children*

Characteristic	Definition
Apnea	Drop in peak flow by ≥90% of pre-event baseline
Obstructive apnea	Apnea for ≥2 breaths associated with respiratory effort
Central apnea	Apnea with absent inspiratory effort *and* Event lasts ≥20 seconds *or* Event lasts ≥2 breaths and associated with arousal or ≥3% oxygen desaturation *or* For infant younger than 1 yr, event lasts ≥2 breaths and associated with decrease in HR to <50 beats/min for ≥5 sec or <60 beats/min for 15 s
Mixed apnea	Apnea for ≥2 breaths with periods of both absent and active respiratory effort, in either order
Hypopnea	Drop in peak flow by ≥30% with *either* ≥3% oxygen desaturation *or* arousal for ≥2 breaths
AHI	No. of apneas and hypopneas per hour of sleep
ODI	No. of oxygen desaturations ≥3% per hour of sleep
Severity scoring for infants†	
Mild	AHI >1 and <5, and Spo_2 <90% for 2–5% of sleep time
Moderate	AHI 5–10, and Spo_2 <90% for 5–10% of sleep time
Severe	AHI >10, and Spo_2 <90% for >10% of sleep time
Severity scoring for children	
OAI‡	>1 is abnormal
AHI§	>1 is abnormal

HR, heart rate; AHI, apnea-hypopnea index; ODI, oxygen desaturation index; Spo_2, oxygen saturation; OAI, obstructive apnea index.
*Definitions adapted and abbreviated from Berry et al. (Berry RB, Budhiraja R, Gottlieb DJ, et al.; American Academy of Sleep Medicine. Rules for scoring respiratory events in sleep: Update of the 2007 AASM Manual for the Scoring of Sleep and Associated Events. Deliberations of the Sleep Apnea Definitions Task Force of the American Academy of Sleep Medicine. *J Clin Sleep Med.* 2012;8:597–619). Criteria can be used for infants and children younger than 18 yr, but according to consensus, a sleep specialist can choose to score children 13 yr or older using adult criteria.
†Adapted from Katz et al. (Katz ES, Mitchell RB, D'Ambrosio CM. Obstructive sleep apnea in infants. *Am J Respir Crit Care Med.* 2012;185: 805–816). Some authors use these criteria for children aged 1 yr or older as well.
‡Adapted from Uliel et al. (Uliel S, Tauman R, Greenfeld M, Sivan Y. Normal polysomnographic respiratory values in children and adolescents. *Chest* 2004;125:872–878).
§Adapted from Chan et al. (Chan J, Edman JC, Koltai PJ. Obstructive sleep apnea in children. *Am Fam Physician* 2004;69:1147–1154).

experts have recommended that a sleep specialist decide whether to use the child or adult scale for scoring obstructive sleep apnea among patients between the ages of 13 and 17 years.[73]

Once the diagnosis of obstructive sleep apnea has been made, further testing should be performed to localize the level of airway obstruction. Supplementing the physical examination, adjunctive testing options include fiberoptic nasopharyngoscopy, rigid bronchoscopy, and sleep endoscopy, which involves placing the child under anesthesia and evaluating the airway for sites of obstruction during spontaneous breathing.[55,74] Lateral cephalograms, dental models, and maxillofacial computed tomographic scans may also be useful for assessing the relationship among the pharyngeal airway, facial skeleton, and skull base.[75,76]

The importance of a comprehensive upper airway evaluation including endoscopic evaluation of the trachea and larynx should not be underestimated. Pediatric patients with syndromic anomalies are at particularly high risk of having associated laryngotracheal anomalies ranging from laryngomalacia to tracheal cartilaginous sleeve.[77] In fact, the prevalence of tracheal cartilaginous sleeve may be significantly underestimated in children with craniofacial syndromes.[78] Fusion of the tracheal cartilages impairs mucociliary clearance and may be associated with significant morbidity in the context of multilevel airway obstruction.[78] Early diagnosis can facilitate a proactive, multidisciplinary approach to management.

OBSTRUCTIVE SLEEP APNEA TREATMENT GUIDELINES

The American Academy of Pediatrics has supplied updated guidelines for treatment of children with obstructive sleep apnea (Table 2).[68] These guidelines pertain to otherwise healthy children and exclude infants younger than 1 year and children with systemic medical or craniofacial conditions, for whom more high-quality treatment data are needed. The American Academy of Pediatrics considers adenotonsillectomy to be first-line treatment for children with a diagnosis of obstructive sleep apnea and adenotonsillar hypertrophy.[68] In a large randomized, controlled trial, children with adenotonsillar hypertrophy underwent watchful waiting or early adenotonsillectomy.[79] Normalization of polysomnographic results was observed in 79 percent of the early adenotonsillectomy group compared with 46 percent of the watchful waiting group. Patients with minimal improvement

Copyright © 2017 American Society of Plastic Surgeons. Unauthorized reproduction of this article is prohibited.

Table 2. Childhood Obstructive Sleep Apnea Treatment Guidelines from the American Academy of Pediatrics*

Intervention	Guideline	Strength of Evidence†
AT	First-line treatment for a child with OSA and clinical examination consistent with AT hypertrophy and no surgical contraindication. High-risk patients, including those with craniofacial anomalies, should be monitored as inpatients.	Recommendation
CPAP	Refer for CPAP if OSA persists after AT or if AT is not performed. CPAP settings are individual and must be titrated over time. Objective monitoring of adherence is important.	Recommendation
Weight loss	Recommend as a treatment adjunct if the patient is obese or overweight. The degree of weight loss required is unknown.	Recommendation
Intranasal corticosteroids	May prescribe for children with mild OSA in whom adenotonsillectomy is contraindicated or for children with mild postoperative OSA (AHI <5/hr).	Option
Reevaluation	All patients with OSA should be clinically reassessed after approximately 6–8 wk of therapy for persisting signs and symptoms; high-risk patients should be monitored with an objective test or referred to a sleep specialist.	Recommendation

AT, adenotonsillectomy; OSA, obstructive sleep apnea; CPAP, continuous positive airway pressure; AHI, apnea-hypopnea index.
*Adapted from Marcus et al. (Marcus CL, Brooks LJ, Draper KA, et al.; American Academy of Pediatrics. Diagnosis and management of childhood obstructive sleep apnea syndrome. *Pediatrics* 2012;130:576–584). These guidelines exclude infants younger than 1 yr and children with craniofacial anomalies and systemic medical conditions.
†Recommendation indicates that the anticipated treatment benefits exceed the harms, but the evidence is not as strong as that of a strong recommendation. Option indicates that the quality of evidence is suspect or carefully performed studies have shown little clear advantage of the treatment approach.

following adenotonsillectomy were more likely to be obese or African American, or to have more severe obstructive sleep apnea.[79]

Children who are not candidates for adenotonsillectomy or who are refractory should be considered for continuous positive airway pressure therapy.[68] Continuous positive airway pressure may be used in children or infants, but close monitoring of mask fit and machine settings is required, as these will change frequently with growth.[69,80] Noncompliance is an important limitation of continuous positive airway pressure and has been reported among 25 to 75 percent of infants and 50 percent of children.[23,81,82] In addition, children receiving continuous positive airway pressure treatment should be observed for side effects of nasal irritation, poor mask fit, dermatitis, skin ulceration, and midface hypoplasia resulting from mask pressure on the nasal, zygomatic, and maxillary bones.[82–84]

ORTHODONTIC AND CRANIOFACIAL TREATMENTS

Although American Academy of Pediatrics guidelines for obstructive sleep apnea focus on management of lymphoid tissue hypertrophy and continuous positive airway pressure, there is increasing evidence that orthodontic and/or craniofacial interventions may benefit infants, healthy children, and children with craniofacial anomalies (Table 3).[18,85–88] Craniofacial treatments have been shown in many instances to prevent tracheotomy or facilitate tracheotomy decannulation.[89,90] This is significant given the complications associated with tracheotomy, ranging from speech and learning impairment to chronic bronchitis, mucus plugging, and death, with mortality rates as high as 8 percent in the pediatric population.[55,90–92] Nonetheless, tracheotomy should always be considered as a potential life-saving procedure, particularly for children with failure to thrive and severe, refractory obstructive sleep apnea.[93]

Orthodontic treatment options for pediatric obstructive sleep apnea include oral appliance therapy and rapid maxillary expansion. Oral appliances may be designed to correct the child's malocclusion and direct growth of the tongue and facial bones. A randomized controlled trial examining oral appliance therapy found a significant reduction in apnea-hypopnea indices among treated subjects,[86] although a Cochrane Review found overall low-quality, insufficient evidence to guide treatment.[85] Rapid maxillary expansion involves distracting the midpalatal suture to widen the maxillary arch and piriform aperture, increasing the volume of the nasal airway and reducing nasal obstruction.[94,95] A meta-analysis associated rapid maxillary expansion with significant reduction in apnea-hypopnea index, although long-term outcomes data are needed.[87] Interestingly, among a cohort of children with obstructive sleep apnea who were candidates for both adenotonsillectomy and rapid maxillary expansion, similar treatment outcomes were achieved regardless of which treatment the patient received first.[17]

Craniofacial surgery is most commonly reserved for children with airway obstruction in the setting of distinct craniofacial anomalies

Copyright © 2017 American Society of Plastic Surgeons. Unauthorized reproduction of this article is prohibited.

Table 3. Systematic Reviews and Meta-Analyses of Orthodontic and Craniofacial Treatments for Pediatric Obstructive Sleep Apnea

Intervention	Description	Study Type	Reference	Findings
Oral appliance therapy	An intraoral appliance corrects the child's mandibular malposition and may guide the tongue into the correct position to facilitate correction of dental occlusion.	Cochrane systematic review	Carvalho et al., 2016[85]	One study by Villa et al.[86] met inclusion criteria. Although Villa et al. noted a significant reduction in AHI and reduction or resolution of respiratory symptoms among treated patients, the level of evidence was considered too low quality to indicate treatment efficacy.
Rapid maxillary expansion	An orthodontic appliance is anchored to the maxillary dentition and distracts the midpalatal suture to increase the transverse dimension of the maxilla and widen the piriform aperture.	Systematic review and meta-analysis	Camacho et al., 2016[87]	17 studies included. AHI decreased from mean 8.9 ± 7.0/hr to 2.7 ± 3.3/hr for 314 children with ≤3-yr follow-up; AHI decreased from mean 7.1 ± 5.7/hr to 1.5 ± 1.8/hr for 52 children with >3-yr follow-up.
Midface distraction osteogenesis	Osteotomies are performed and distractors are used to advance and reposition the midface to improve the patient's airway, dental occlusion, and aesthetics.	Systematic review	Taylor et al., 2014[18]	16 studies met criteria for analysis. Study quality was low and consisted of retrospective case series. Objective measures were not consistently provided. Qualitatively, favorable outcomes in patient respiratory status, tracheotomy decannulation, and cephalometric dimensions were noted, although all patients did not experience airway improvement.
MDO	Mandibular osteotomies are performed to mobilize the anterior dental arch, and distraction is performed to lengthen the mandible and advance the tongue base.	Meta-analysis	Ow et al., 2008[88]	178 studies were included involving 539 patients who received unilateral MDO and 646 patients who received bilateral MDO. Most children had Pierre Robin sequence or hemifacial/craniofacial microsomia. MDO prevented tracheotomy and/or intubation in 84 of 92 neonates/infants. OSA/respiratory distress was improved or relieved in 65 of 67 children with OSA.

AHI, apnea-hypopnea index; MDO, mandibular distraction osteogenesis; OSA, obstructive sleep apnea.

(Fig. 2). For infants with mandibular hypoplasia, conservative interventions are often attempted first, including prone positioning, tongue-lip adhesion, and/or upper airway bypass with a nasopharyngeal tube.[59,96–100] Infants refractory to conservative management may be candidates for mandibular distraction osteogenesis. A meta-analysis found that 91.3 percent of neonates and infants were able to avoid intubation or tracheotomy after mandibular distraction osteogenesis.[88] Although postoperative polysomnographic data are limited, mandibular distraction osteogenesis has been associated with significant apnea-hypopnea index reduction. A study of five children who underwent mandibular distraction osteogenesis as infants because of Pierre Robin sequence or severe micrognathia and had 3 or more years of follow-up revealed that four of them had a residual apnea-hypopnea index less than 1.[101]

Children with significant impairment of maxillary growth may also benefit from facial skeletal surgery. Before skeletal maturation, Le Fort III distraction osteogenesis may be safely performed; however, Le Fort I advancement is risky because of potential disruption of maxillary teeth as they develop and migrate. Transsutural distraction osteogenesis has been described as an alternative to maxillary osteotomy in the skeletally immature patient and may significantly improve midface hypoplasia.[102] Once the child is skeletally mature, revision distraction or definitive orthognathic surgery may be performed.[103]

Multiple studies have shown an association between midface distraction and improvements in airway volume and obstructive sleep apnea.[104,105] A systematic review of children undergoing Le Fort II or III distraction osteogenesis found evidence to suggest an improvement in respiratory status, but the evidence was low quality, with inadequate quantitative outcomes data.[18] Nonetheless, there are some compelling quantitative data to suggest that selecting an appropriate distraction vector that optimizes the position of the facial skeleton in relation to the skull base may improve patients' respiratory outcomes.[106] Among a cohort of syndromic patients undergoing Le Fort III distraction, patients whose apnea-hypopnea index improved had an average sella-nasion-subspinale angle

Copyright © 2017 American Society of Plastic Surgeons. Unauthorized reproduction of this article is prohibited.

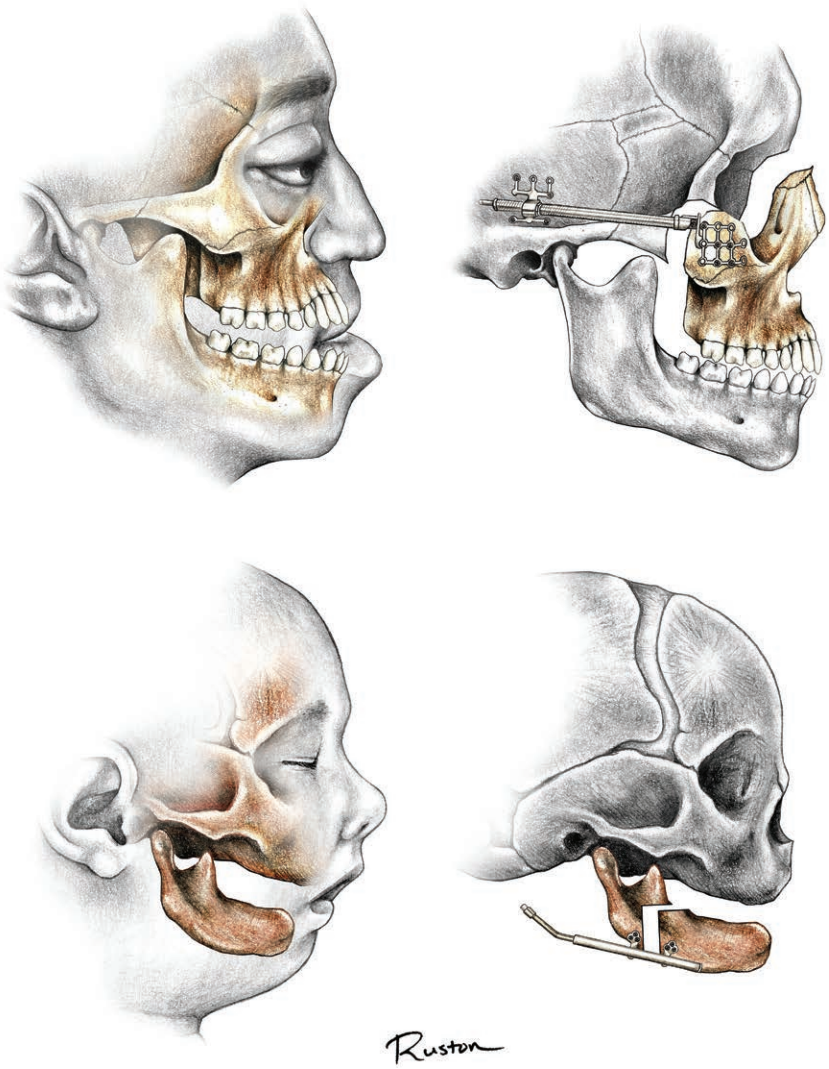

Fig. 2. Distraction osteogenesis for craniofacial advancement and airway expansion. (*Above*) Midface distraction osteogenesis. A Le Fort III distraction, which advances the malar, orbital, maxillary, and nasal bones, is represented. (*Below*) Mandibular distraction osteogenesis. This procedure advances the dental arch with its attached tongue base, thereby expanding the retrolingual airway.

increase of 22.8 degrees compared with an average increase of 7.6 degrees among patients without apnea-hypopnea index improvement. There was no difference in the amount of linear skeletal advancement between these groups, suggesting that improvements in the sella-nasion-subspinale angle correlate more strongly with postoperative reduction in apnea-hypopnea index than the amount of linear skeletal advancement.[106]

CONCLUSIONS

Pediatric obstructive sleep apnea represents a broad spectrum of disease resulting from neuromotor dysfunction, lymphoid tissue hypertrophy, and craniofacial skeletal dysmorphology. Although adenotonsillectomy is the standard for treatment and benefits most healthy children, continuous positive airway pressure, medications, orthodontic treatment, and craniofacial distraction should be considered for refractory patients and patients with multilevel obstruction in the setting of craniofacial anomalies. There are some limited but promising quantitative data to suggest an improvement in respiratory status with both midface and mandibular distraction osteogenesis procedures. Future prospective studies are needed to improve diagnosis of pediatric

Copyright © 2017 American Society of Plastic Surgeons. Unauthorized reproduction of this article is prohibited.

obstructive sleep apnea and clarify the role of craniofacial interventions for healthy children and children with craniofacial differences. In addition, given the prevalence and morbidity of obstructive sleep apnea among adults,[107] greater insight into pediatric obstructive sleep apnea will help us understand the continuum or discontinuum of this disease process—whether infants and children with obstructive sleep apnea continue to have obstructive sleep apnea as adults, and whether craniofacial characteristics associated with upper airway obstruction evolve or persist into adulthood.[108]

Delora L. Mount, M.D.
Division of Plastic and Reconstructive Surgery
University of Wisconsin, Madison
600 Highland Avenue
Madison, Wis. 53792
mount@surgery.wisc.edu

REFERENCES

1. Redline S, Tishler PV, Schluchter M, Aylor J, Clark K, Graham G. Risk factors for sleep-disordered breathing in children: Associations with obesity, race, and respiratory problems. *Am J Respir Crit Care Med.* 1999;159:1527–1532.
2. MacLean JE, Hayward P, Fitzgerald DA, Waters K. Cleft lip and/or palate and breathing during sleep. *Sleep Med Rev.* 2009;13:345–354.
3. Hoeve LJ, Pijpers M, Joosten KF. OSAS in craniofacial syndromes: An unsolved problem. *Int J Pediatr Otorhinolaryngol.* 2003;67(Suppl 1):S111–S113.
4. Driessen C, Joosten KF, Bannink N, et al. How does obstructive sleep apnoea evolve in syndromic craniosynostosis? A prospective cohort study. *Arch Dis Child.* 2013;98:538–543.
5. Anderson IC, Sedaghat AR, McGinley BM, Redett RJ, Boss EF, Ishman SL. Prevalence and severity of obstructive sleep apnea and snoring in infants with Pierre Robin sequence. *Cleft Palate Craniofac J.* 2011;48:614–618.
6. Isono S, Shimada A, Utsugi M, Konno A, Nishino T. Comparison of static mechanical properties of the passive pharynx between normal children and children with sleep-disordered breathing. *Am J Respir Crit Care Med.* 1998;157:1204–1212.
7. Brouillette RT, Fernbach SK, Hunt CE. Obstructive sleep apnea in infants and children. *J Pediatr.* 1982;100:31–40.
8. Lipton AJ, Gozal D. Treatment of obstructive sleep apnea in children: Do we really know how? *Sleep Med Rev.* 2003;7:61–80.
9. Farber JM. Clinical practice guideline: Diagnosis and management of childhood obstructive sleep apnea syndrome. *Pediatrics* 2002;110:1255–1257; author reply 1255.
10. Ali NJ, Pitson D, Stradling JR. Sleep disordered breathing: Effects of adenotonsillectomy on behaviour and psychological functioning. *Eur J Pediatr.* 1996;155:56–62.
11. Gozal D. Sleep-disordered breathing and school performance in children. *Pediatrics* 1998;102:616–620.
12. Laurikainen E, Aitasalo K, Erkinjuntti M, Wanne O. Sleep apnea syndrome in children: Secondary to adenotonsillar hypertrophy? *Acta Otolaryngol Suppl.* 1992;492:38–41.
13. Tang A, Gropler M, Duggins AL, et al. Gaps in evidence: Management of pediatric obstructive sleep apnea without tonsillar hypertrophy. *Laryngoscope* 2016;126:758–762.
14. Guilleminault C, Partinen M, Praud JP, Quera-Salva MA, Powell N, Riley R. Morphometric facial changes and obstructive sleep apnea in adolescents. *J Pediatr.* 1989;114:997–999.
15. Tasker C, Crosby JH, Stradling JR. Evidence for persistence of upper airway narrowing during sleep, 12 years after adenotonsillectomy. *Arch Dis Child.* 2002;86:34–37.
16. Ishman SL, Tang A, Cohen AP, et al. Decision making for children with obstructive sleep apnea without tonsillar hypertrophy. *Otolaryngol Head Neck Surg.* 2016;154:527–531.
17. Guilleminault C, Monteyrol PJ, Huynh NT, Pirelli P, Quo S, Li K. Adeno-tonsillectomy and rapid maxillary distraction in pre-pubertal children, a pilot study. *Sleep Breath.* 2011;15:173–177.
18. Taylor BA, Brace M, Hong P. Upper airway outcomes following midface distraction osteogenesis: A systematic review. *J Plast Reconstr Aesthet Surg.* 2014;67:891–899.
19. Standards and indications for cardiopulmonary sleep studies in children. American Thoracic Society. *Am J Respir Crit Care Med.* 1996;153:866–878.
20. Valera FC, Avelino MA, Pettermann MB, et al. OSAS in children: Correlation between endoscopic and polysomnographic findings. *Otolaryngol Head Neck Surg.* 2005;132:268–272.
21. McNamara F, Sullivan CE. Sleep-disordered breathing and its effects on sleep in infants. *Sleep* 1996;19:4–12.
22. Urquhart DS, Tan HL. Sleep disordered breathing at the extremes of age: Infancy. *Breathe (Sheff.)* 2016;12:e1–e11.
23. Katz ES, Mitchell RB, D'Ambrosio CM. Obstructive sleep apnea in infants. *Am J Respir Crit Care Med.* 2012;185:805–816.
24. Marcus CL, McColley SA, Carroll JL, Loughlin GM, Smith PL, Schwartz AR. Upper airway collapsibility in children with obstructive sleep apnea syndrome. *J Appl Physiol (1985)* 1994;77:918–924.
25. Marcus CL, Lutz J, Carroll JL, Bamford O. Arousal and ventilatory responses during sleep in children with obstructive sleep apnea. *J Appl Physiol (1985)* 1998;84:1926–1936.
26. Katz ES, Marcus CL, White DP. Influence of airway pressure on genioglossus activity during sleep in normal children. *Am J Respir Crit Care Med.* 2006;173:902–909.
27. Greenfeld M, Tauman R, DeRowe A, Sivan Y. Obstructive sleep apnea syndrome due to adenotonsillar hypertrophy in infants. *Int J Pediatr Otorhinolaryngol.* 2003;67:1055–1060.
28. Muzumdar H, Arens R. Diagnostic issues in pediatric obstructive sleep apnea. *Proc Am Thorac Soc.* 2008;5:263–273.
29. Zandieh SO, Padwa BL, Katz ES. Adenotonsillectomy for obstructive sleep apnea in children with syndromic craniosynostosis. *Plast Reconstr Surg.* 2013;131:847–852.
30. Willington AJ, Ramsden JD. Adenotonsillectomy for the management of obstructive sleep apnea in children with congenital craniosynostosis syndromes. *J Craniofac Surg.* 2012;23:1020–1022.
31. Amonoo-Kuofi K, Phillips SP, Randhawa PS, Lane R, Wyatt ME, Leighton SE. Adenotonsillectomy for sleep-disordered breathing in children with syndromic craniosynostosis. *J Craniofac Surg.* 2009;20:1978–1980.
32. Verhulst SL, Van Gaal L, De Backer W, Desager K. The prevalence, anatomical correlates and treatment of sleep-disordered breathing in obese children and adolescents. *Sleep Med Rev.* 2008;12:339–346.
33. Dayyat E, Kheirandish-Gozal L, Sans Capdevila O, Maarafeya MMA, Gozal D. Obstructive sleep apnea in children: Relative contributions of body mass index and adenotonsillar hypertrophy. *Chest* 2009;136:137–144.
34. Zucconi M, Caprioglio A, Calori G, et al. Craniofacial modifications in children with habitual snoring and obstructive sleep apnoea: A case-control study. *Eur Respir J.* 1999;13:411–417.

Copyright © 2017 American Society of Plastic Surgeons. Unauthorized reproduction of this article is prohibited.

35. Ozdemir H, Altin R, Söğüt A, et al. Craniofacial differences according to AHI scores of children with obstructive sleep apnoea syndrome: Cephalometric study in 39 patients. *Pediatr Radiol.* 2004;34:393–399.
36. Oosterkamp BC, Remmelink HJ, Pruim GJ, Hoekema A, Dijkstra PU. Craniofacial, craniocervical, and pharyngeal morphology in bilateral cleft lip and palate and obstructive sleep apnea patients. *Cleft Palate Craniofac J.* 2007;44:1–7.
37. Juliano ML, Machado MA, de Carvalho LB, et al. Polysomnographic findings are associated with cephalometric measurements in mouth-breathing children. *J Clin Sleep Med.* 2009;5:554–561.
38. Chung Leng Muñoz I, Beltri Orta P. Comparison of cephalometric patterns in mouth breathing and nose breathing children. *Int J Pediatr Otorhinolaryngol.* 2014;78:1167–1172.
39. Pirilä-Parkkinen K, Pirttiniemi P, Pääkkö E, Tolonen U, Nieminen P, Löppönen H. Pharyngeal airway in children with sleep-disordered breathing in relation to head posture. *Sleep Breath.* 2012;16:737–746.
40. Solow B, Kreiborg S. Soft-tissue stretching: A possible control factor in craniofacial morphogenesis. *Scand J Dent Res.* 1977;85:505–507.
41. Solow B, Skov S, Ovesen J, Norup PW, Wildschiødtz G. Airway dimensions and head posture in obstructive sleep apnoea. *Eur J Orthod.* 1996;18:571–579.
42. Pirilä-Parkkinen K, Pirttiniemi P, Nieminen P, Tolonen U, Pelttari U, Löppönen H. Dental arch morphology in children with sleep-disordered breathing. *Eur J Orthod.* 2009;31:160–167.
43. Peltomäki T. The effect of mode of breathing on craniofacial growth: Revisited. *Eur J Orthod.* 2007;29:426–429.
44. Zettergren-Wijk L, Forsberg CM, Linder-Aronson S. Changes in dentofacial morphology after adeno-/tonsillectomy in young children with obstructive sleep apnoea: A 5-year follow-up study. *Eur J Orthod.* 2006;28:319–326.
45. Muntz H, Wilson M, Park A, Smith M, Grimmer JF. Sleep disordered breathing and obstructive sleep apnea in the cleft population. *Laryngoscope* 2008;118:348–353.
46. Hermann NV, Jensen BL, Dahl E, Bolund S, Kreiborg S. A comparison of the craniofacial morphology in 2-month-old unoperated infants with unilateral complete cleft lip and palate, and unilateral incomplete cleft lip. *J Craniofac Genet Dev Biol.* 1999;19:80–93.
47. Hermann NV, Kreiborg S, Darvann TA, Jensen BL, Dahl E, Bolund S. Early craniofacial morphology and growth in children with unoperated isolated cleft palate. *Cleft Palate Craniofac J.* 2002;39:604–622.
48. Corbo M, Dujardin T, de Maertelaer V, Malevez C, Glineur R. Dentocraniofacial morphology of 21 patients with unilateral cleft lip and palate: A cephalometric study. *Cleft Palate Craniofac J.* 2005;42:618–624.
49. Rose E, Thissen U, Otten JE, Jonas I. Cephalometric assessment of the posterior airway space in patients with cleft palate after palatoplasty. *Cleft Palate Craniofac J.* 2003;40:498–503.
50. Lypka M, Bidros R, Rizvi M, et al. Posterior pharyngeal augmentation in the treatment of velopharyngeal insufficiency: A 40-year experience. *Ann Plast Surg.* 2010;65:48–51.
51. Valnicek SM, Zuker RM, Halpern LM, Roy WL. Perioperative complications of superior pharyngeal flap surgery in children. *Plast Reconstr Surg.* 1994;93:954–958.
52. de Serres LM, Deleyiannis FW, Eblen LE, Gruss JS, Richardson MA, Sie KC. Results with sphincter pharyngoplasty and pharyngeal flap. *Int J Pediatr Otorhinolaryngol.* 1999;48:17–25.
53. Liao YF, Noordhoff MS, Huang CS, et al. Comparison of obstructive sleep apnea syndrome in children with cleft palate following Furlow palatoplasty or pharyngeal flap for velopharyngeal insufficiency. *Cleft Palate Craniofac J.* 2004;41:152–156.
54. Agarwal T, Sloan GM, Zajac D, Uhrich KS, Meadows W, Lewchalermwong JA. Speech benefits of posterior pharyngeal flap are preserved after surgical flap division for obstructive sleep apnea: Experience with division of 12 flaps. *J Craniofac Surg.* 2003;14:630–636.
55. Boston M, Rutter MJ. Current airway management in craniofacial anomalies. *Curr Opin Otolaryngol Head Neck Surg.* 2003;11:428–432.
56. Marcus CL, Keens TG, Bautista DB, von Pechmann WS, Ward SL. Obstructive sleep apnea in children with Down syndrome. *Pediatrics* 1991;88:132–139.
57. Moraleda-Cibrián M, Edwards SP, Kasten SJ, Buchman SR, Berger M, O'Brien LM. Obstructive sleep apnea pretreatment and posttreatment in symptomatic children with congenital craniofacial malformations. *J Clin Sleep Med.* 2015;11:37–43.
58. Burstein FD, Cohen SR, Scott PH, Teague GR, Montgomery GL, Kattos AV. Surgical therapy for severe refractory sleep apnea in infants and children: Application of the airway zone concept. *Plast Reconstr Surg.* 1995;96:34–41.
59. Perkins JA, Sie KC, Milczuk H, Richardson MA. Airway management in children with craniofacial anomalies. *Cleft Palate Craniofac J.* 1997;34:135–140.
60. Hopper RA, Kapadia H, Morton T. Normalizing facial ratios in Apert syndrome patients with Le Fort II midface distraction and simultaneous zygomatic repositioning. *Plast Reconstr Surg.* 2013;132:129–140.
61. Shen YF, Vargervik K, Oberoi S, Chigurupati R. Facial skeletal morphology in growing children with Pierre Robin sequence. *Cleft Palate Craniofac J.* 2012;49:553–560.
62. Kapadia H, Shetye PR, Grayson BH, McCarthy JG. Cephalometric assessment of craniofacial morphology in patients with Treacher Collins syndrome. *J Craniofac Surg.* 2013;24:1141–1145.
63. Avantaggiato A, Carinci F, Curioni C. Apert's syndrome: Cephalometric evaluation and considerations on pathogenesis. *J Craniofac Surg.* 1996;7:23–31.
64. Carinci F, Avantaggiato A, Curioni C. Crouzon syndrome: Cephalometric analysis and evaluation of pathogenesis. *Cleft Palate Craniofac J.* 1994;31:201–209.
65. Ma X, Forte AJ, Persing JA, Alonso N, Berlin NL, Steinbacher DM. Reduced three-dimensional airway volume is a function of skeletal dysmorphology in Treacher Collins syndrome. *Plast Reconstr Surg.* 2015;135:382e–392e.
66. Rosen HM, Whitaker LA. Cranial base dynamics in craniofacial dysostosis. *J Maxillofac Surg.* 1984;12:56–61.
67. Nie X. Cranial base in craniofacial development: Developmental features, influence on facial growth, anomaly, and molecular basis. *Acta Odontol Scand.* 2005;63:127–135.
68. Marcus CL, Brooks LJ, Draper KA, et al.; American Academy of Pediatrics. Diagnosis and management of childhood obstructive sleep apnea syndrome. *Pediatrics* 2012;130:576–584.
69. Marcus CL, Brooks LJ, Draper KA, et al.; American Academy of Pediatrics. Diagnosis and management of childhood obstructive sleep apnea syndrome. *Pediatrics* 2012;130:e714–e755.
70. Chan J, Edman JC, Koltai PJ. Obstructive sleep apnea in children. *Am Fam Physician* 2004;69:1147–1154.
71. Uliel S, Tauman R, Greenfeld M, Sivan Y. Normal polysomnographic respiratory values in children and adolescents. *Chest* 2004;125:872–878.
72. MacLean JE, Fitzsimons D, Fitzgerald DA, Waters KA. The spectrum of sleep-disordered breathing symptoms and

Copyright © 2017 American Society of Plastic Surgeons. Unauthorized reproduction of this article is prohibited.

respiratory events in infants with cleft lip and/or palate. *Arch Dis Child.* 2012;97:1058–1063.
73. Berry RB, Budhiraja R, Gottlieb DJ, et al.; American Academy of Sleep Medicine. Rules for scoring respiratory events in sleep: Update of the 2007 AASM Manual for the Scoring of Sleep and Associated Events. Deliberations of the Sleep Apnea Definitions Task Force of the American Academy of Sleep Medicine. *J Clin Sleep Med.* 2012;8:597–619.
74. Myatt HM, Beckenham EJ. The use of diagnostic sleep nasendoscopy in the management of children with complex upper airway obstruction. *Clin Otolaryngol Allied Sci.* 2000;25:200–208.
75. Guilleminault C, Li KK, Khramtsov A, Pelayo R, Martinez S. Sleep disordered breathing: Surgical outcomes in prepubertal children. *Laryngoscope* 2004;114:132–137.
76. Cohen SR, Holmes RE, Machado L, Magit A. Surgical strategies in the treatment of complex obstructive sleep apnoea in children. *Paediatr Respir Rev.* 2002;3:25–35.
77. Papay FA, McCarthy VP, Eliachar I, Arnold J. Laryngotracheal anomalies in children with craniofacial syndromes. *J Craniofac Surg.* 2002;13:351–364.
78. Pickrell BB, Meaike JD, Cañadas KT, Chandy BM, Buchanan EP. Tracheal cartilaginous sleeve in syndromic craniosynostosis: An underrecognized source of significant morbidity and mortality. *J Craniofac Surg.* 2017;28:696–699.
79. Marcus CL, Moore RH, Rosen CL, et al.; Childhood Adenotonsillectomy Trial (CHAT). A randomized trial of adenotonsillectomy for childhood sleep apnea. *N Engl J Med.* 2013;368:2366–2376.
80. McNamara F, Sullivan CE. Obstructive sleep apnea in infants and its management with nasal continuous positive airway pressure. *Chest* 1999;116:10–16.
81. Adeleye A, Ho A, Nettel-Aguirre A, Buchhalter J, Kirk V. Noninvasive positive airway pressure treatment in children less than 12 months of age. *Can Respir J.* 2016;2016:7654631.
82. Marcus CL, Ward SL, Mallory GB, et al. Use of nasal continuous positive airway pressure as treatment of childhood obstructive sleep apnea. *J Pediatr.* 1995;127:88–94.
83. Fauroux B, Lavis JF, Nicot F, et al. Facial side effects during noninvasive positive pressure ventilation in children. *Intensive Care Med.* 2005;31:965–969.
84. Roberts SD, Kapadia H, Greenlee G, Chen ML. Midfacial and dental changes associated with nasal positive airway pressure in children with obstructive sleep apnea and craniofacial conditions. *J Clin Sleep Med.* 2016;12:469–475.
85. Carvalho FR, Lentini-Oliveira DA, Prado LB, Prado GF, Carvalho LB. Oral appliances and functional orthopaedic appliances for obstructive sleep apnoea in children. *Cochrane Database Syst Rev.* 2016;10:CD005520.
86. Villa MP, Bernkopf E, Pagani J, Broia V, Montesano M, Ronchetti R. Randomized controlled study of an oral jaw-positioning appliance for the treatment of obstructive sleep apnea in children with malocclusion. *Am J Respir Crit Care Med.* 2002;165:123–127.
87. Camacho M, Chang ET, Song SA, et al. Rapid maxillary expansion for pediatric obstructive sleep apnea: A systematic review and meta-analysis. *Laryngoscope* 2017;127:1712–1719.
88. Ow AT, Cheung LK. Meta-analysis of mandibular distraction osteogenesis: Clinical applications and functional outcomes. *Plast Reconstr Surg.* 2008;121:54e–69e.
89. McCarthy JG, Katzen JT, Hopper R, Grayson BH. The first decade of mandibular distraction: Lessons we have learned. *Plast Reconstr Surg.* 2002;110:1704–1713.
90. Morovic CG, Monasterio L. Distraction osteogenesis for obstructive apneas in patients with congenital craniofacial malformations. *Plast Reconstr Surg.* 2000;105:2324–2330.
91. Li HY, Lee LA. Sleep-disordered breathing in children. *Chang Gung Med J.* 2009;32:247–257.
92. Carron JD, Derkay CS, Strope GL, Nosonchuk JE, Darrow DH. Pediatric tracheotomies: Changing indications and outcomes. *Laryngoscope* 2000;110:1099–1104.
93. Darrow DH. Surgery for pediatric sleep apnea. *Otolaryngol Clin North Am.* 2007;40:855–875.
94. Pirelli P, Saponara M, Guilleminault C. Rapid maxillary expansion in children with obstructive sleep apnea syndrome. *Sleep* 2004;27:761–766.
95. Monini S, Malagola C, Villa MP, et al. Rapid maxillary expansion for the treatment of nasal obstruction in children younger than 12 years. *Arch Otolaryngol Head Neck Surg.* 2009;135:22–27.
96. Tapia IE, Karamessinis L, Bandla P, et al. Polysomnographic values in children undergoing puberty: Pediatric vs. adult respiratory rules in adolescents. *Sleep* 2008;31:1737–1744.
97. Denny AD, Amm CA, Schaefer RB. Outcomes of tongue-lip adhesion for neonatal respiratory distress caused by Pierre Robin sequence. *J Craniofac Surg.* 2004;15:819–823.
98. Abel F, Bajaj Y, Wyatt M, Wallis C. The successful use of the nasopharyngeal airway in Pierre Robin sequence: An 11-year experience. *Arch Dis Child.* 2012;97:331–334.
99. Ahmed J, Marucci D, Cochrane L, Heywood RL, Wyatt ME, Leighton SE. The role of the nasopharyngeal airway for obstructive sleep apnea in syndromic craniosynostosis. *J Craniofac Surg.* 2008;19:659–663.
100. Parhizkar N, Saltzman B, Grote K, et al. Nasopharyngeal airway for management of airway obstruction in infants with micrognathia. *Cleft Palate Craniofac J.* 2011;48:478–482.
101. Lin SY, Halbower AC, Tunkel DE, Vanderkolk C. Relief of upper airway obstruction with mandibular distraction surgery: Long-term quantitative results in young children. *Arch Otolaryngol Head Neck Surg.* 2006;132:437–441.
102. Tong H, Wang X, Song T, et al. Trans-sutural distraction osteogenesis for midfacial hypoplasia in growing patients with cleft lip and palate: Clinical outcomes and analysis of skeletal changes. *Plast Reconstr Surg.* 2015;136:144–155.
103. Klement KA, Black JS, Denny AD. Versatility of distraction osteogenesis for the craniofacial skeleton. *J Craniofac Surg.* 2016;27:565–570.
104. Xu H, Yu Z, Mu X. The assessment of midface distraction osteogenesis in treatment of upper airway obstruction. *J Craniofac Surg.* 2009;20(Suppl 2):1876–1881.
105. Flores RL, Shetye PR, Zeitler D, et al. Airway changes following Le Fort III distraction osteogenesis for syndromic craniosynostosis: A clinical and cephalometric study. *Plast Reconstr Surg.* 2009;124:590–601.
106. Ettinger RE, Hopper RA, Sandercoe G, et al. Quantitative computed tomographic scan and polysomnographic analysis of patients with syndromic midface hypoplasia before and after Le Fort III distraction advancement. *Plast Reconstr Surg.* 2011;127:1612–1619.
107. Garg RK, Afifi AM, Sanchez R, King TW. Obstructive sleep apnea in adults: The role of upper airway and facial skeletal surgery. *Plast Reconstr Surg.* 2016;138:889–898.
108. Marcus CL. Obstructive sleep apnea syndrome: Differences between children and adults. *Sleep* 2000;23(Suppl 4): S140–S141.

Copyright © 2017 American Society of Plastic Surgeons. Unauthorized reproduction of this article is prohibited.